



Sex Cord Tumor With Annular Tubules in Association With Endometrioma: A Case Report

Sepideh Khodaverdi¹, Aboufazel Mehdizadeh Kashi¹, Banafsheh Tajbakhsh^{1*}, Alireza Sadeghipour², Samaneh Rokhgireh¹, Leila Nazari¹

Abstract

Endometriosis is a prevalent inflammatory gynecologic disease in women of reproductive age that affects up to 15% of the women. It has been reported that majority of the malignant tumors are associated with endometriosis along with clear cell and invasive endometrioid ovarian malignancy. However, in this case presentation, we have identified an association of endometriosis and sex cord tumor with annular tubules. It was considered as a disease with some conditions which make it appear not malignant for sharing some properties related to cancer and some other malignant tumors are associated with the endometriotic type and clear cell ovarian cancer. However, in this case report, we have identified coincidence of endometriosis and sex cord tumor with annular tubules. The ultimate goal of this study was to draw the attention of the readers to the point that endometrioma could be accompanied not only by clear cell and endometrioid ovarian cancer but also by other ovarian cancers. This case was considered in the study to conduct further research if similar cases are observed.

Keywords: Endometriosis, Ovarian cancer, Sex cord tumor, Annular tubules malignancy, Endometrioma

Introduction

Endometriosis is defined as a common inflammatory gynecologic disorder in women and an estrogen-dependent condition during reproductive age that is seen in nearly 15% of women (1). A chronic inflammatory process inside or outside the pelvic region is caused by endometrial tissue in a site other than the uterine cavity (2). Endometriosis has three different entities: ovarian, peritoneal and rectovaginal areas (3). At first, it was thought that the disease is a benign condition since it may share a number of features with cancer (4, 5). Although it involves different pelvic site, most of the time it was detected in ovaries with endometrioma (6). Most lethal gynecologic tumors are ovarian cancer with a prevalence of 3.7% in all female cases (7). Sampson in 1927 for the first time described the correlation between endometriosis and ovarian malignancy. Several studies have done to find the correlation between endometriosis and gynecological malignancy and this studies have suggested that ovarian cancer is prevalent in 0.7 to 17% of endometriosis cases (5, 8). Malignant transformation of an endometrioma has a different mechanism that includes genomic alteration, inflammatory process, oxidative stress and increased estrogen (1). It has been reported that majority of the malignant tumors are associated with endometriosis along with clear cell and invasive endometrioid ovarian cancer (1, 9). However, in this case presentation, we have an association of endometriosis and sex cord tumor with

annular tubules.

Case Presentation

A virgin female aged 20 years was admitted to our hospital with a complaint of severe pain in right lower quadrant of the abdomen. She suffered from nausea and vomited several times. She had pain for one month but it became worse during the last week before admission. Clinical examination found tenderness and deep tenderness in right lower quadrant of the abdomen. Her vital sign was normal. She had a regular menstrual cycle without a family history of malignancy. She had done a sonography at first episode of abdominal pain and the imaging depicted a 62.63 mm simple cyst in the right ovary. She took 21 contraceptive pills for one cycle 5 days prior to admission. Other imaging showed a 65.70 mm cyst in the right ovary in endometrioma appearance. On the day of admission, we had done a transanal sonography which showed a 60 mm endometrioid cyst in the right ovary.

Lab result indicated an increase in CA19-9 and CA125 with normal CEA and HE4 but ROMA showed high risk (Table 1).

She became a candidate for the operation because of the abdominal pain and was operated by laparoscopic route. There was an 8 cm unilateral endometrioma cyst in right ovary with many endometrial patches in the anterior and posterior cul-de-sac and uterosacral ligaments. There were many adhesions in the pelvic and around the right



Table 1. Patient's Laboratory Findings

CEA	1.06	NL
CA19,9	66/86	
CA125	127/78	
HE4	56.1	NL
ROMA	10.8	High risk
BHCG	<5	NL
AFP	<0.5	NL

CEA: Carcinoembryonic Antigen; CA 19,9: Carbohydrate Antigen 19-9; CA125: Cancer Antigen 125; HE4: Human Epididymis Protein 4; ROMA: Risk for Ovarian Malignancy Algorithm; BHCG: Beta-Human Chorionic Gonadotropin; AFP: Alpha-fetoprotein

ovary. Ovarian cystectomy, adhesiolysis and cutting of patches were done. The pathologic examination of the tissue sample from the patient showed coexistence of endometriosis with sex Cord tumor with annular tubule (Figures 1 and 2). In this patient, due to endometriotic nature of the cyst and fertility age of the patient we performed ovarian cystectomy to treat the disorder. The patient was also followed up by an oncologist for further study and unilateral salpingo-oophrectomy and staging were done.

Discussion

Initially, sex cord tumor with annular tubule (SCTAT) was defined by Scully in 1970 (10). SCTAT was considered to be a rare condition and accounts for lower than 1% of all sex cord-Stromal tumors. Differential diagnosis of SCTAT includes Sertoli cell tumor, gonadoblastoma and microfollicular granulosa cell tumor. In Sertoli cell tumors, we do not see complex tubules. In microfollicular granulosa cells, we do not see many hyaline bodies in lumens of tubular structures. In Gonadoblastoma, we could see stromal elements and hyaline bodies but in SCTAT, germ cell component and abnormal gonadal development are seen (10). SCTAT is a hormone-secreting tumor with estrogen and progesterin secretions and its clinical finding is mainly due to this secretion.

Patients may have irregular menses, post-menopausal bleeding, precocious puberty based on their ages although our case was a woman of reproductive age with no clinical symptoms or signs for high estrogen product. She had regular menstrual cycles and normal puberty but she suffered from the abdominal pain. Several studies showed a strong association between SCTAT with Peutz-Jegers syndrome (PJS), hence they were classified into 2 types, one with PJS and other without PJS (11). Patient with PJS and SCTAT usually has bilateral, multiple, and benign tumor smaller than 3 cm in size and those without PJS has unilateral, larger tumor (close to 33 cm), which may behave in a malignant fashion (10). Nonetheless, there were not any features of PJS in the present case. There are many coexisting conditions between SCTAT and other pathologies but most of them appear as single case phenomenon such as Turner syndrome, Gonadoblastoma,

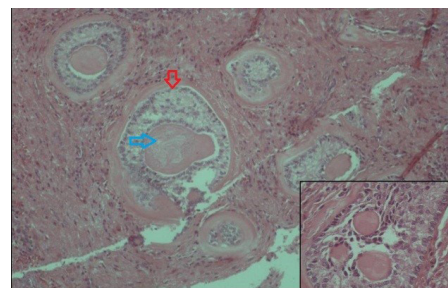


Figure 1. Discrete islands and annular structures composed of polyhedral cells with pale cytoplasm (Red arrow) which are arranged around amorphous, pale-staining material (Blue arrow). Inset: higher view of the lesion (H&E stain, X100).

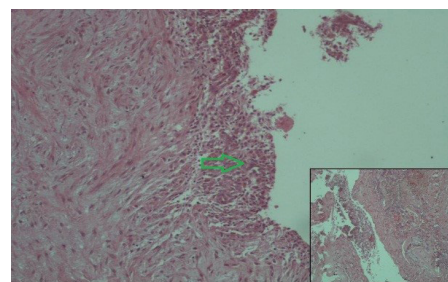


Figure 2. Cyst wall which is focally lined by endometrial mucosa (Green arrow) with surface erosion. Inset: A thin layer of endometrial mucosa in wall of cyst. (H&E stain, X100).

endometrial carcinoma, and endometriosis of the fallopian tube (12).

We only found one case of co-occurrence of SCTAT with endometriotic cyst which was reported in 2014. Since SCTAT is a rare condition, standard protocol does not exist for this pathology. Although the surgical procedure is the first steps in managing the patient's disease, saving fertility is very important in a patient of Reproductive age (11). Unilateral salpingo-oophorectomy is recommended for a patient with an intact capsule and unilateral ovarian tumor involvement. Wedge resection of another ovary is recommended in patients with PJS and patient with a suspected lesion in the contralateral ovary. In these patients, long-term prognosis is unknown. Nowadays, we manage these patients based on the previous studies in the literature.

This guideline recommended surgery with preservation of fertility (if possible) (12).

Conclusions

The ultimate goal of this study was to draw the attention of readers to the point that endometrioma could be accompanied not only by clear cell and endometrioid ovarian cancer but also by other ovarian cancers. This case was considered in the study to conduct further research if similar cases are observed. There may be a genetic relationship between endometriosis and cancer and it is recommended to be assessed in future studies.

Conflict of Interests

Authors declare that they have no conflict of interests.

Ethical Issues

The protocol was approved by the Ethics Committee of the Rasoul-e-Akram general university hospital and written informed consent was obtained from the patient for publication of this case report.

Financial Support

This study was financially supported by Iran University of Medical Science and Endometriosis and Gynecological Disorder Research Center.

References

- Grandi G, Toss A, Cortesi L, Botticelli L, Volpe A, Cagnacci A. The Association between Endometriomas and Ovarian Cancer: Preventive Effect of Inhibiting Ovulation and Menstruation during Reproductive Life. *Biomed Res Int.* 2015;2015:751571. doi:10.1155/2015/751571
- Bulun SE. Endometriosis. *N Engl J Med.* 2009;360(3):268-279. doi:10.1056/NEJMra0804690
- Nisolle M, Donnez J. Peritoneal endometriosis, ovarian endometriosis, and adenomyotic nodules of the rectovaginal septum are three different entities. *Fertil Steril.* 1997;68(4):585-596. doi:10.1016/S0015-0282(97)00191-X
- Gupta A, Sharma R, Mahajan N, Vij A, Gupta A, Kaushal V. Endometriotic cyst in one ovary and Mixed Germ Cell Tumour in other ovary in an unmarried girl. *The Southeast Asian Journal of Case Report and Review.* 2016;5(2):2232-2236.
- Worley MJ, Welch WR, Berkowitz RS, Ng SW. Endometriosis-associated ovarian cancer: a review of pathogenesis. *Int J Mol Sci.* 2013;14(3):5367-5379. doi:10.3390/ijms14035367
- Kurman RJ, Shih Ie M. The origin and pathogenesis of epithelial ovarian cancer: a proposed unifying theory. *Am J Surg Pathol.* 2010;34(3):433-443. doi:10.1097/PAS.0b013e3181cf3d79
- Ferlay J, Shin HR, Bray F, Forman D, Mathers C, Parkin DM. Estimates of worldwide burden of cancer in 2008: GLOBOCAN 2008. *Int J Cancer.* 2010;127(12):2893-2917. doi:10.1002/ijc.25516
- Heidemann LN, Hartwell D, Heidemann CH, Jochumsen KM. The relation between endometriosis and ovarian cancer - a review. *Acta Obstet Gynecol Scand.* 2014;93(1):20-31. doi:10.1111/aogs.12255
- Lan C, Huang X, Lin S, Cai M, Liu J. Endometrial stromal sarcoma arising from endometriosis: a clinicopathological study and literature review. *Gynecol Obstet Invest.* 2012;74(4):288-297. doi:10.1159/000341706
- Erhan SS, Gul AE, Keser SH, Acar S, Senu S. Sex Cord Stromal Tumor with Annular Tubules: A Case Report. *Gynecology & Obstetrics Case Report.* 2016;2(1):1-3.
- Qian Q, You Y, Yang J, et al. Management and prognosis of patients with ovarian sex cord tumor with annular tubules: a retrospective study. *BMC Cancer.* 2015;15:270. doi:10.1186/s12885-015-1277-y
- Singh M, Mandal S, Majumdar K. Sex Cord Tumor with Annular Tubules: An Incidental Finding in an Endometriotic Cyst—The First Known Cooccurrence. *Biomed Res Int.* 2014;2014:970243. doi:10.1155/2014/970243

© 2018 The Author (s); This is an open-access article distributed under the terms of the Creative Commons Attribution License (<http://creativecommons.org/licenses/by/4.0>), which permits unrestricted use, distribution, and reproduction in any medium, provided the original work is properly cited.